“All for one and one for All” ????

TONY YSUNZA
IAN JACKSON CRANIOFACIAL AND CLEFT PALATE CLINIC
BEAUMONT
MSHA 2017. TROY, MI

DISCLOSURE

No conflict of interest

No financial disclosures

GOALS

- **UNDERSTAND V P I.**
- **V P S VARIES INDIVIDUAL - INDIVIDUAL**
- **IMPORTANCE OF IMAGING PROCEDURES FOR ASSESSING V P I**
- **INTERACTION OF MULTIDISCIPLINARY MANAGEMENT**

V P
DYSFUNCTION
V P
LEARNING
DISORDER
V P
INCOMPETENCE
the name
GAME
VELO
PALATINE
INCOMPETENCE
CONGENITAL
SHORT VELUM
SUBMUCOUS
CLEFT PALATE
VELAR PARESIS
OCCULT
SUBMUCOUS
CLEFT PALATE

V P I

- **V P I = HYPERNASALITY WITH OR W O NASAL EMISSION; WITH OR W O NASAL REGURGITATION**
- **DIFFERENT ETIOLOGIES**

TEAM EFFORT

A QUE LE TIRAS CUANDO SUENAS MEXICANO ?

DAVID BLOOM, MD; DONALD GIBSON, MD, KENNETH SHAHEEN, MD; KONGKRIT CHAIYASATE, MD; MATTHEW RONTAL, MD; MELISSA McBRIEN, MD

FRIENDS OR ENEMIES ?

- **V P I W COMP. ARTIC. (SLP + SURGERY)**
- **V P I W O COMP. ARTIC. (SURGERY)**

V P I

- **V P I W COMP.ARTIC. (20 - 25% IN US, CANADA AND REST OF FIRST WORLD. BUT CAN GO UP TO > 50% IN THIRD WORLD (SEVERAL FACTORS)**

SURGICAL TREATMENT
V P I

- SAME SURGICAL PROCEDURE – TECHNIQUE FOR EVERY CASE ?
- HOW TO MODIFY SURGICAL TECHNIQUE ?
- HOW TO DEFINE OUTCOME ? (“AHI SE VA”… “Q TANTO ES TANTITO ?”… “MA O MENOS”… “GOOD SPEECH”)

International Journal of Pediatric Otorhinolaryngology

Vol. 78, Issue 10,
October, 2014

Speech outcomes at age 5 and 10 years in unilateral cleft lip and palate after one-stage palatal repair with minimal incision technique – A longitudinal perspective

Jill Nyberg [a,b,c,]*, Petra Peterson [b,d], Anette Lohmander

a,c a Division of Speech and Language Pathology, Department of Clinical Science, Intervention and Technology, Karolinska Institutet, Stockholm, Sweden b Department of Reconstructive Plastic Surgery, Karolinska University Hospital, Stockholm, Sweden c Department of Speech Pathology, Karolinska University Hospital, Stockholm, Sweden d Department of Molecular Medicine and Surgery, Karolinska Institutet, Stockholm, Sweden

- **PALATAL REPAIR AROUND 1 YEAR (10 – 18 MONTHS)**
- **AFTER 10 YEAR FOLLOW – UP = 45% RESIDUAL V P I**
- **C A < 25 %**
- **ALL RESIDUAL V P I 'S TREATED W PHARYNGEAL FLAP**

NEVER OPERATE W O ANATOMICAL AND PHYSIOLOGICAL ASSESSMENT OF V P S

- VIDEONASOPHARYNGOSCOPY
- VIDEOFLUOROSCOPY : MULTIPLANAR VIDEOFLUOROSCOPY

V N P

- **DIRECT VISUALIZATION OF THE ENTIRE VOCAL TRACT THROUGH THE NOSE**
- **FLEXIBLE ENDOSCOPE**
- **< 3 MM DIAMETER**
- **RECORDING DEVICE WITH SOUND**
- ***TOLERANCE – DISCOMFORT = <u>2 – 3</u> OF <u>0 – 3</u>.**
- ***<u>NOT VERY GOOD</u>)**

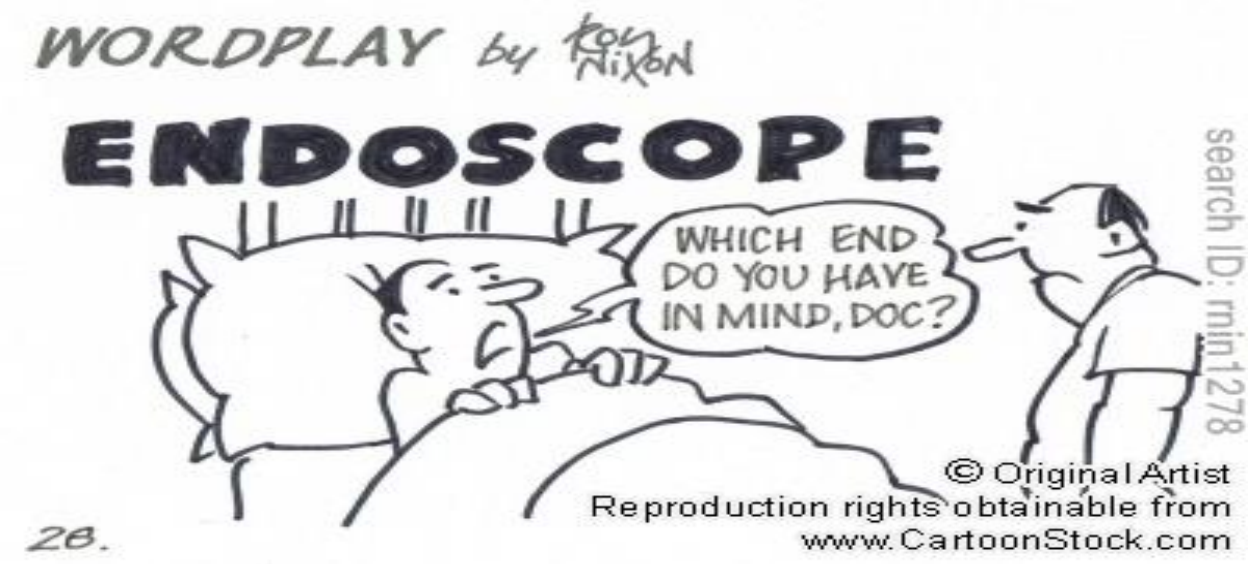

- **PREOP VIDEOFLUOROSCOPY**
- **INTRAOPERATIVE ENDOSCOPY**

M P V F

- **DYNAMIC ASSESSMENT (VIDEO)**
- **ANALYSIS ON VIDEO**
- **(CORONAL, SAGITTAL, AXIAL**
- ***TOLERANCE – DISCOMFORT**
- **0 – 1 OF 0 – 3.**
- **(**VERY GOOD)**



Wilhelm Roentgen
1895
15 min exposure !!
(his wife, WHO ELSE ?)

Wilhelm's wife on viewing her skeleton:
"I have seen my own death"

M P V F (CONT.)

- **EXAM IS NEEDED. NO OTHER STUDY PROVIDES SAME INFO WITHOUT IONIZING RADIATION (ACTUAL SIZE MEASUREMENT, LPW MOTION AND DEPTH (3 – D CONCEPT).**
- **MULTIPLANAR**

M P V F (CONT.)

- PULSED V F VS CONTINUOUS.
- AVOID MAGNIFICATION
- TOWER CLOSE TO PATIENT

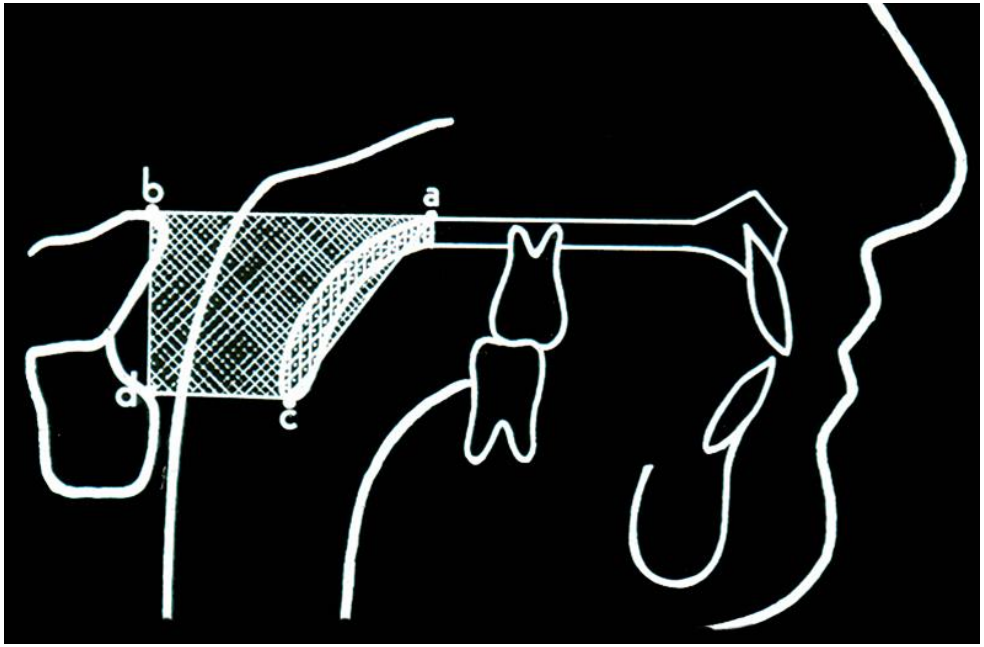

M P V F (CONT.)

- LIMIT FLUOROSCOPY TIME (40 SEC) = ENHANCE COMPLIANCE *
- AVOID PLANES (AXIAL WHEN SCOPE AVAILABLE)
- CONING TO AVOID RADIOSENSITIVE STRUCTURES SUCH AS LENS AND THYROID

ENHANCE COMPLIANCE, REDUCE ANXIETY: STORY BOOK

You will seat on mommy or daddy's lap
The doctor will squirt a little "white water" into your nose with a tiny plastic tube. You will feel a funny tickle in your nose

M P V F (CONT.)

- **KEEP TRACK OF RADIATION DOSE**
- **EFFECTIVE RADIATION DOSE < 50 mSv OR mGy**

VIDEOFLUOROSCOPY

- MilliSieverts
- Multiplanar Videofluoroscopy (Coronal, Sagittal, axial (optional) and obliques (optional)
- **n = 98 PATIENTS**
- **X = 2. 88 mSv**
- SD = **1.575 mSv**
- RANGE = **0.40 mSv – 8.75 mSv**

M P V F

- **ASSESSMENT AND MEASUREMENTS**
- **D V D**

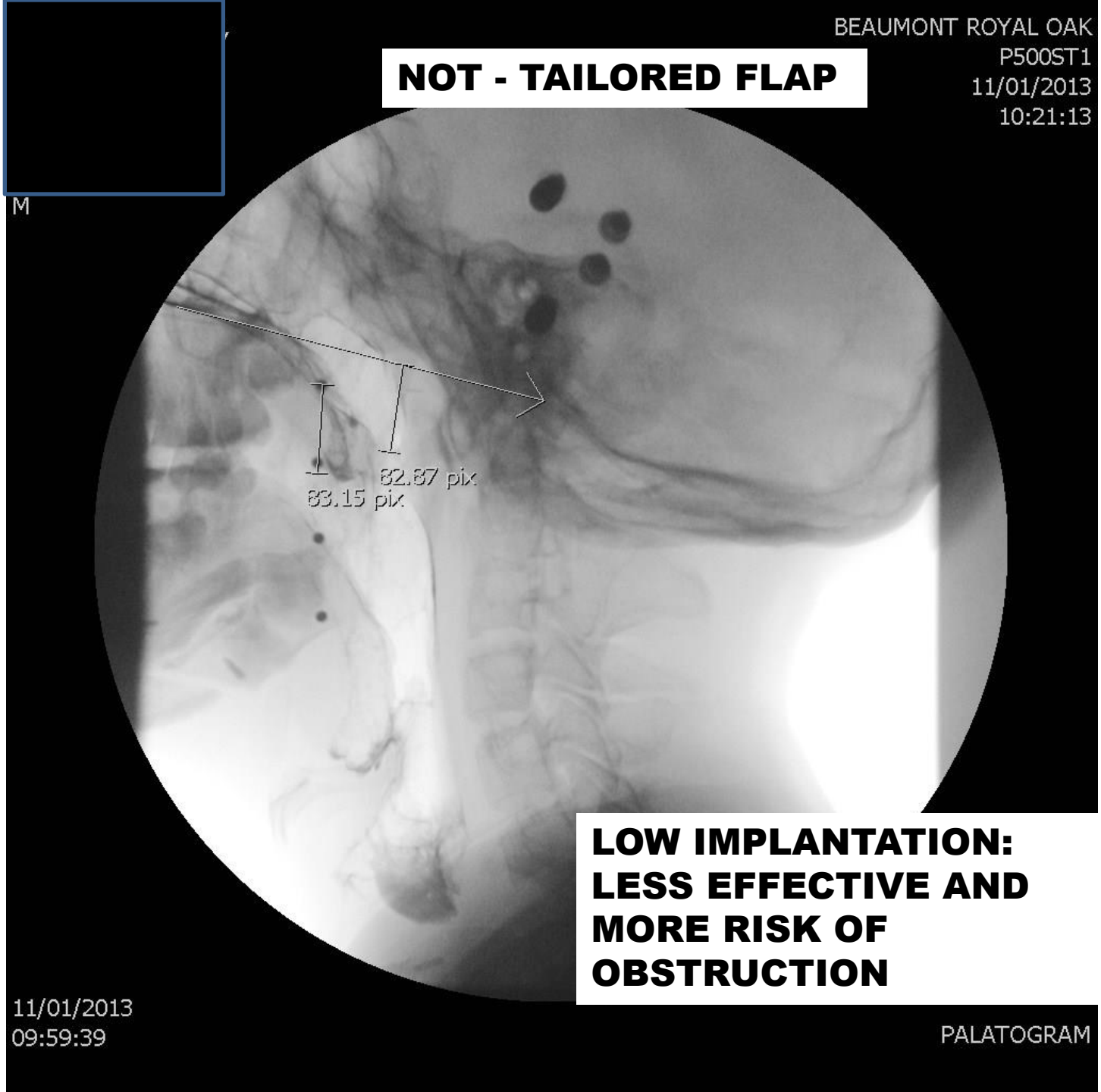
BEAUMONT ROYAL OAK
P500ST1
11/01/2013
10:21:13
NOT - TAILORED FLAP
M
82.87 pix
83.15 pix
LOW IMPLANTATION:
LESS EFFECTIVE AND
MORE RISK OF
OBSTRUCTION
11/01/2013
09:59:39
PALATOGRAM

William Beaumont Hospital
P500ST1
11/04/2013
10:05:07
TAILOR-MADE FLAP
21.02 pix
56.14 pix
HIGH IMPLANTATION =
EFFECTIVE
NO OBSTRUCTION
11/04/2013
08:52:22
PALATOGRAM

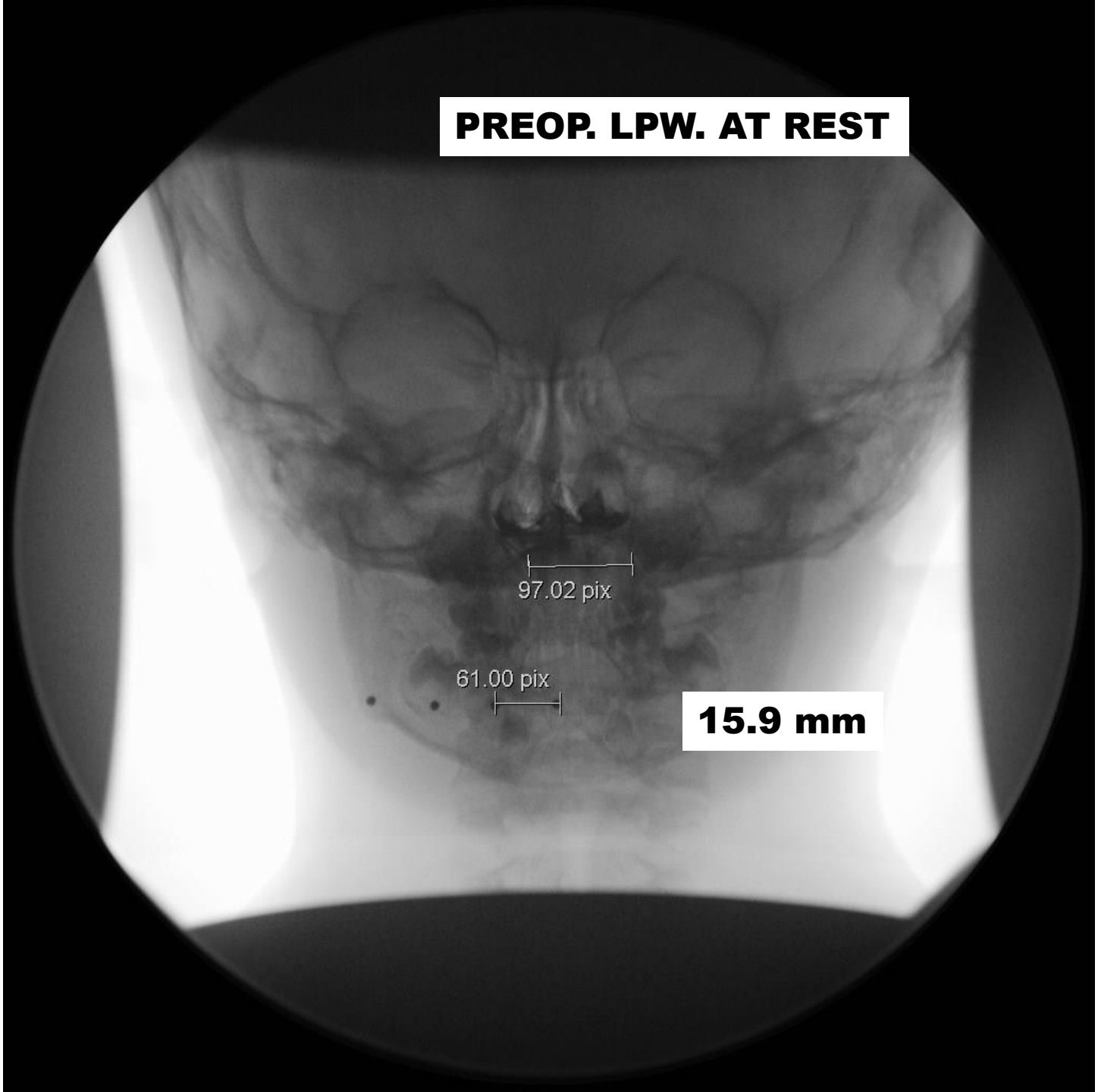
PREOP. LPW. AT REST
97.02 pix
61.00 pix
15.9 mm

PREOP. LPW. SUST. /S/
0.99 cm (ui)
70.03 pix
9.9 mm

TAILOR MADE FLAP CLOSURE DURING SPEECH

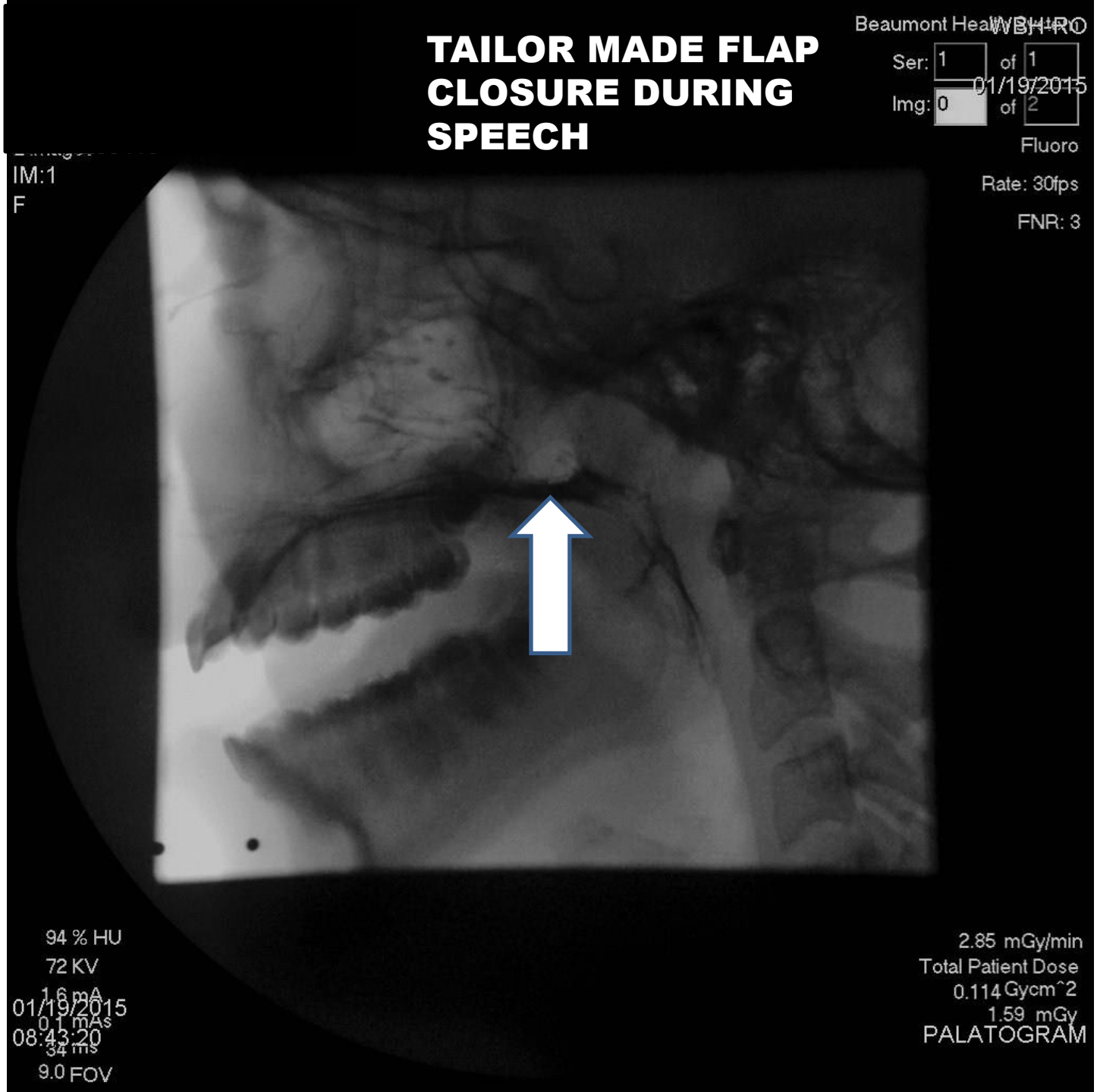

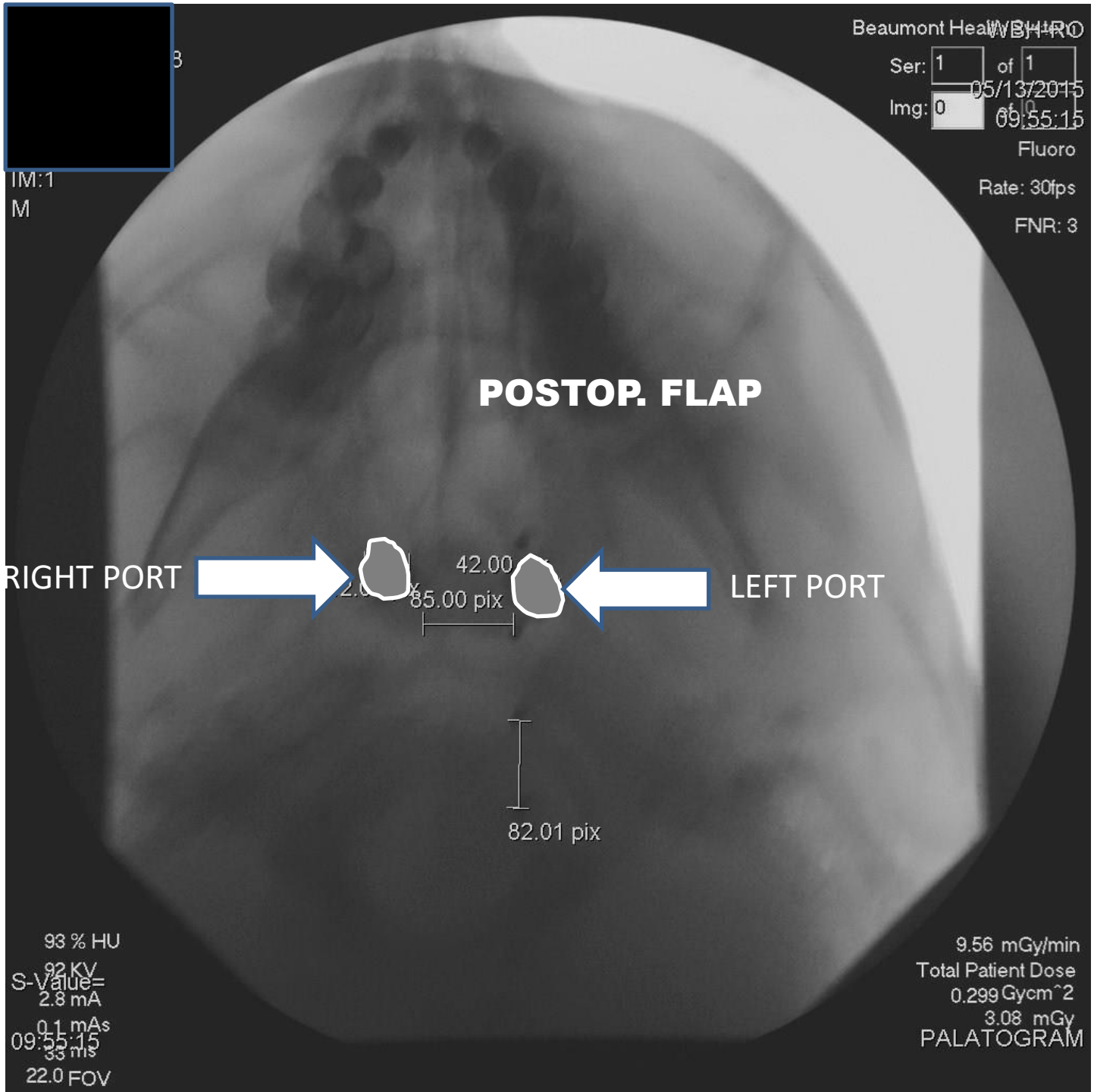
Beaumont Health
Ser: 1 of 1
Img: 0 of 0
05/13/2015
09:55:15
Fluoro
Rate: 30fps
FNR: 3
IM:1
M
POSTOP. FLAP
RIGHT PORT
LEFT PORT
42.00
85.00 pix
82.01 pix
93 % HU
92 KV
S-Value=
2.8 mA
0.1 mAs
09:55:15
33 ms
22.0 FOV
9.56 mGy/min
Total Patient Dose
0.299 Gycm^2
3.08 mGy
PALATOGRAM

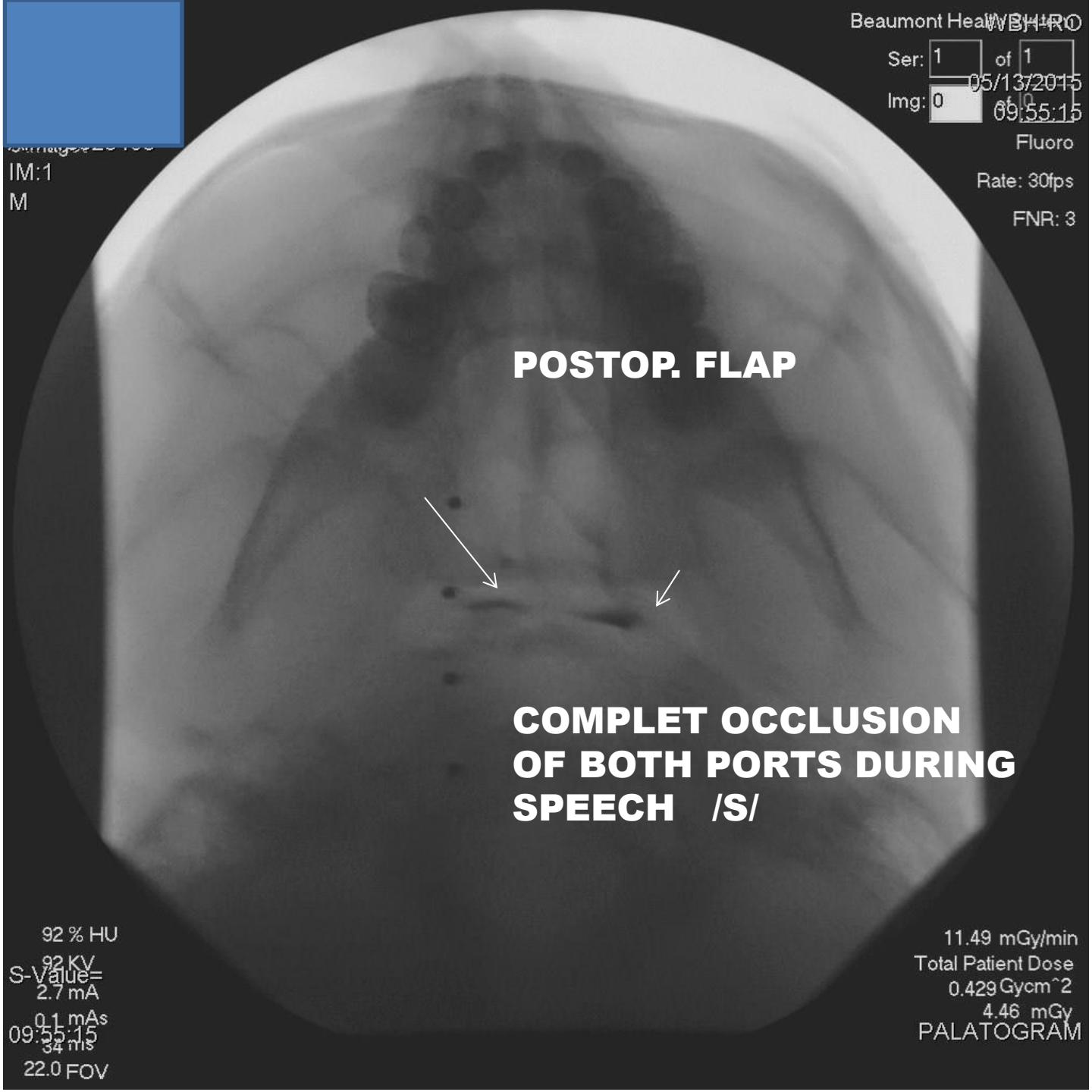
Beaumont Healt
WBH-RO
Ser: 1 of 1
Img: 0 of 0
05/13/2015
09:55:15
Fluoro
Rate: 30fps
FNR: 3
IM:1
M
POSTOP. FLAP
COMPLET OCCLUSION
OF BOTH PORTS DURING
SPEECH /S/
92 % HU
92 KV
S-Value=
2.7 mA
0.1 mAs
34 ms
09:55:15
22.0 FOV
11.49 mGy/min
Total Patient Dose
0.429 Gycm^2
4.46 mGy
PALATOGRAM

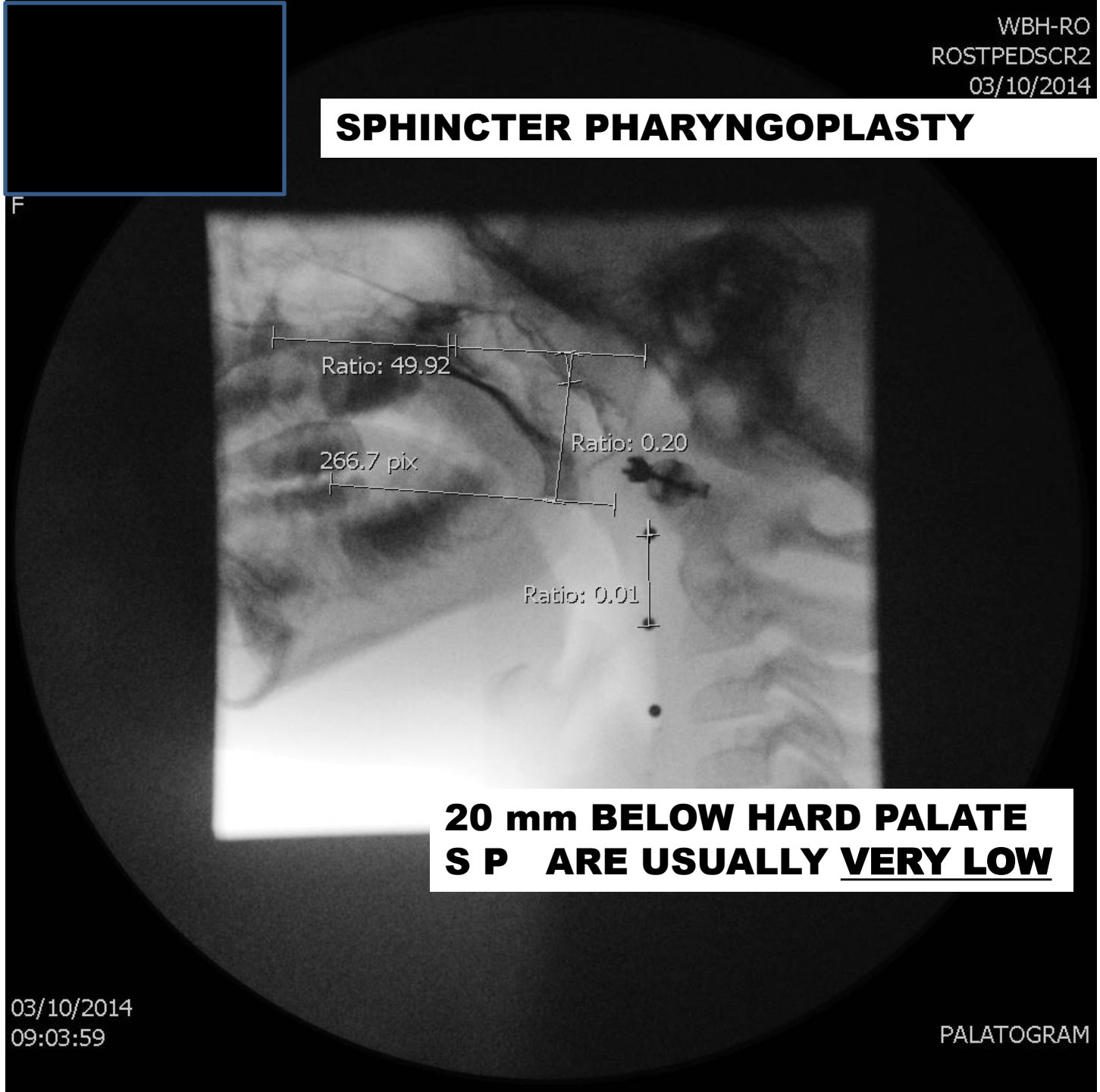
WBH-RO
ROSTPEDSCR2
03/10/2014
SPHINCTER PHARYNGOPLASTY
F
Ratio: 49.92
Ratio: 0.20
266.7 pix
Ratio: 0.01
20 mm BELOW HARD PALATE
S P ARE USUALLY VERY LOW
03/10/2014
09:03:59
PALATOGRAM

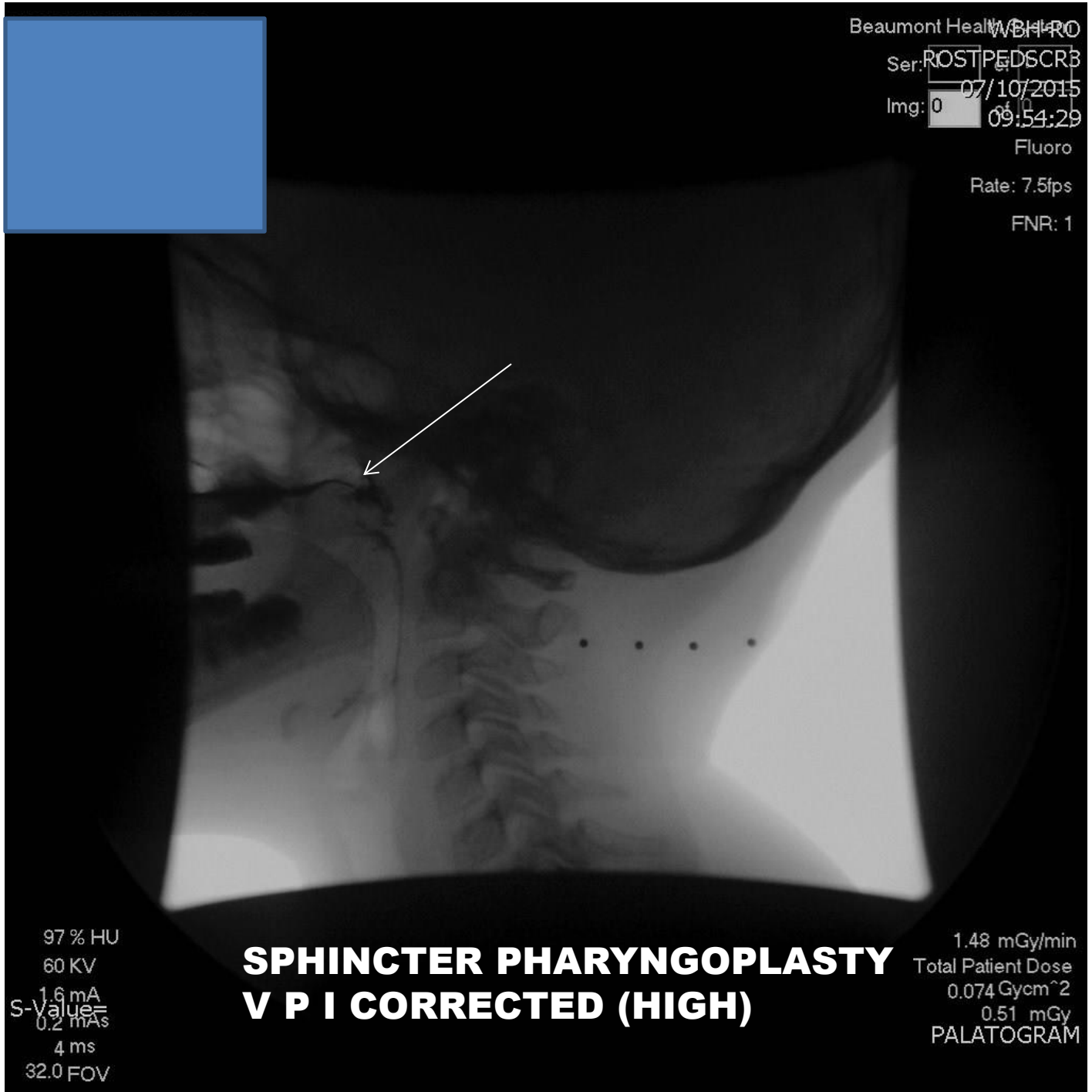
Beaumont Health System
VBH-RO
Ser: ROSTPEDSCR3
Img: 0
07/10/2015
09:54:29
Fluoro
Rate: 7.5fps
FNR: 1
97 % HU
60 KV
1.6 mA
S-Value=
0.2 mAs
4 ms
32.0 FOV
SPHINCTER PHARYNGOPLASTY
V P I CORRECTED (HIGH)
1.48 mGy/min
Total Patient Dose
0.074 Gycm^2
0.51 mGy
PALATOGRAM

TAILOR MADE PHARYNGEAL FLAPS W INTRAOP V N P

"Nurse, get on the internet, go to SURGERY.COM, scroll down and click on the 'Are you totally lost?' icon."

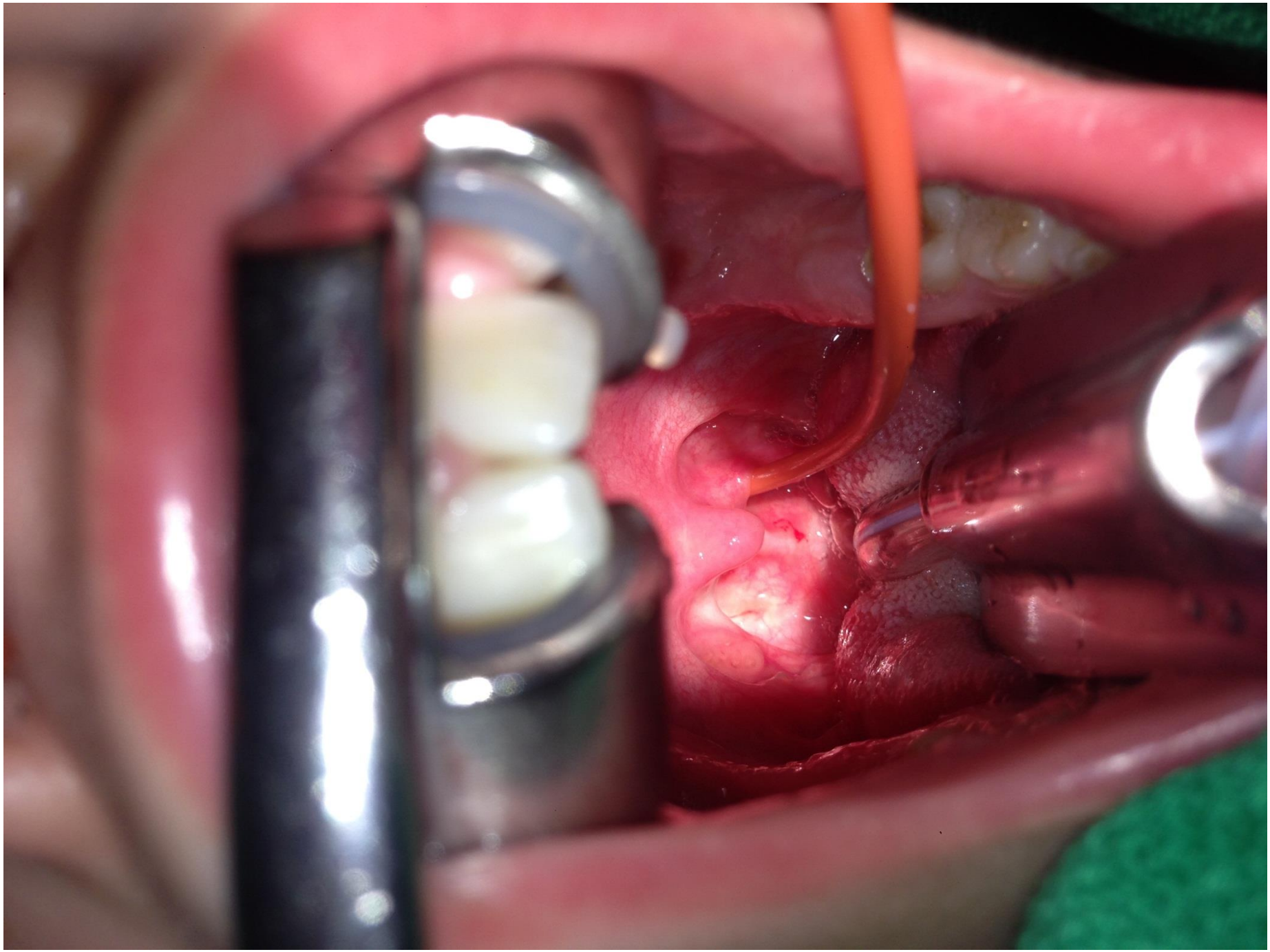

INTRAOPERATIVE V N P

- **WHY NOT ONLY M P V F ? ?**
- **WHY IS V N P NECESSARY ??**

8 YO. SMCP. POST FURLOW. RESIDUAL HYPERNASALITY AND NASAL EMISSION

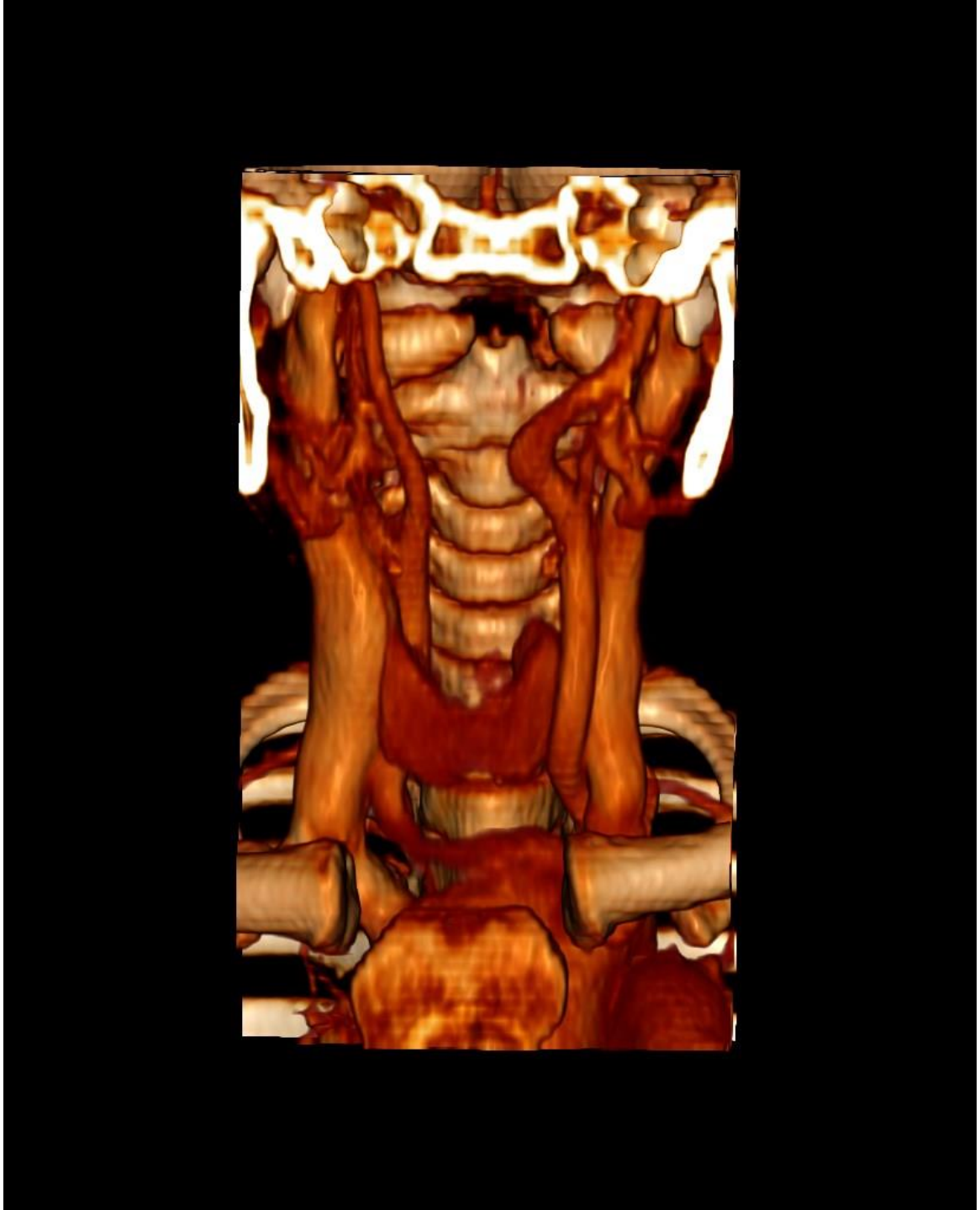

LEFT I C A
MEDIALLY
DISPLACED

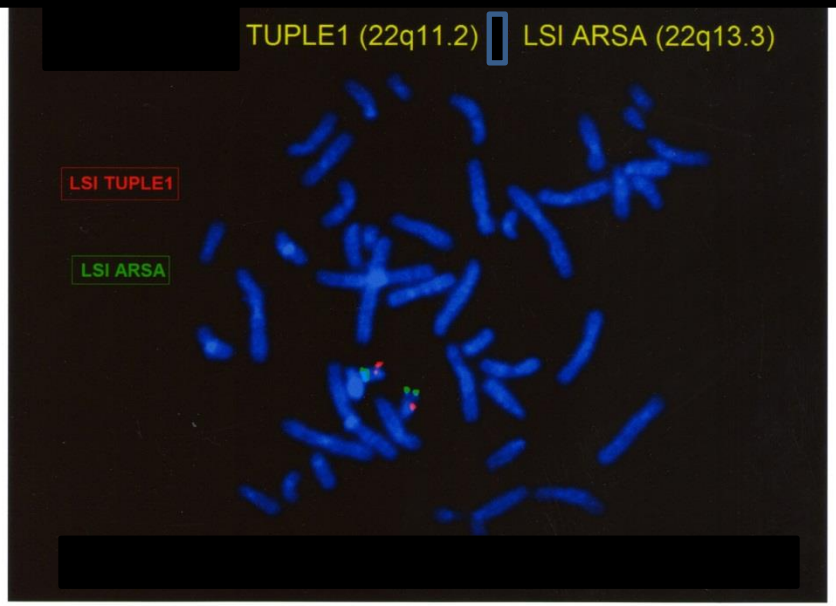

22q13.3: 4 signals present

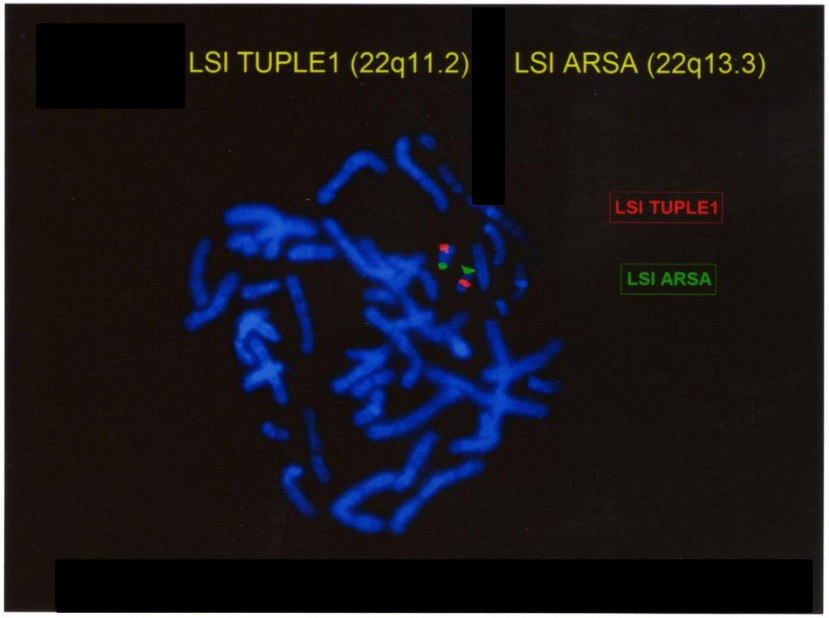

22q11.2: 4 signals present

Beaumont Health System
Ser: 1 of 1
Img: 0 of 2
Fluoro
Rate: 30fps
FNR: 3
POST T & A AND
POST FLAP
2mm BELOW H P
10.05 pix
55.15 pix
96 % HU
62 KV
1.6 mA
0.1 mAs
04/18/2014
09:57:27
12.0 FOV
1.75 mGy/min
Total Patient Dose
0.178 Gycm^2
1.29 mGy
PALATOGRAM

22Q11.2 POSTOP MRI FLAP

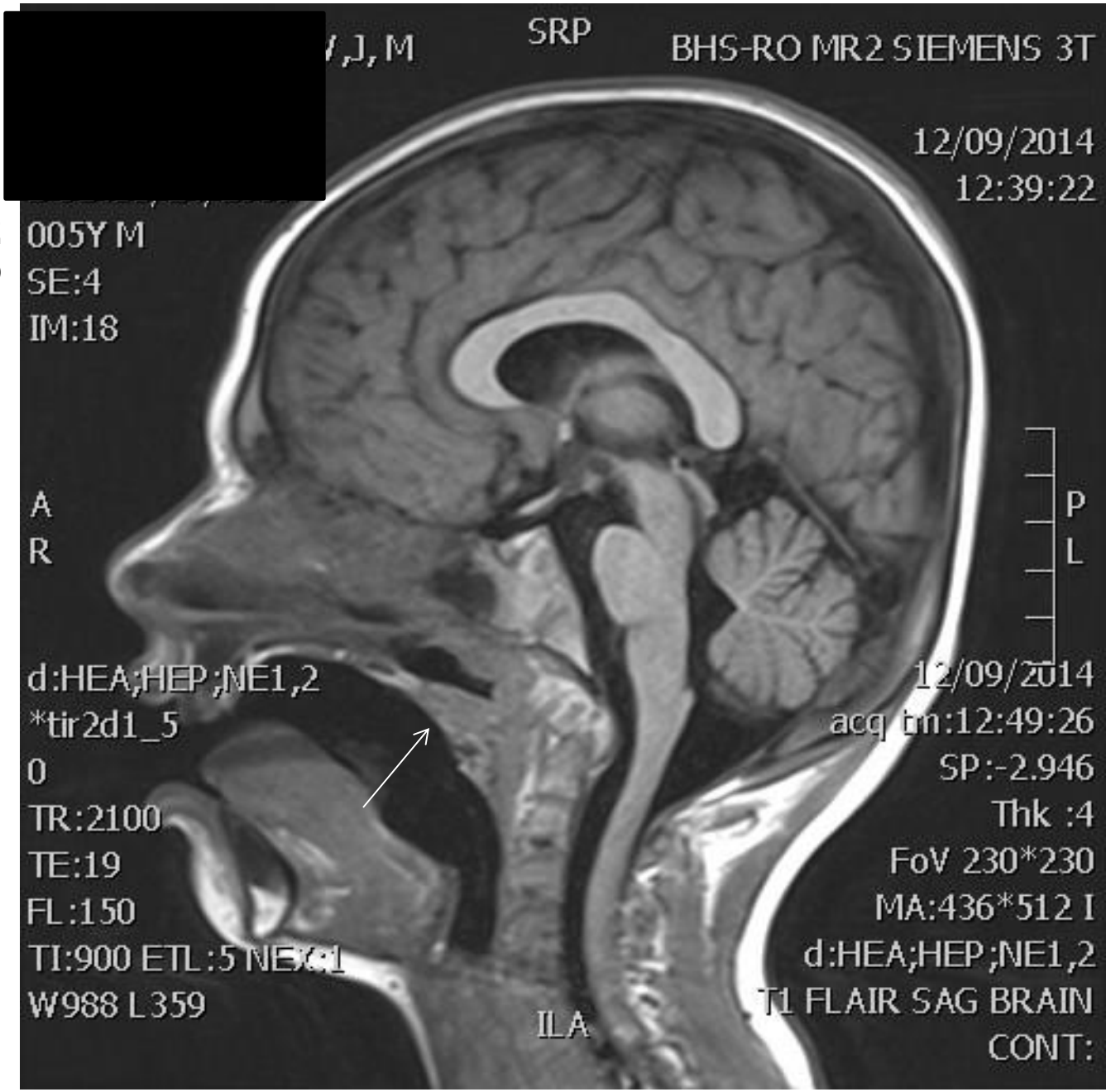

VELOPHARYNGEAL SURGERY

- FAT TRANSFER FOR CORRECTING SELECTED CASES OF V P I
- CAREFUL SELECTION OF CASES
- FAILED PHARYNGEAL FLAPS OR BORDERLINE VELOPHARYNGEAL CLOSURE AFTER VELOPLASTY
- INTRAOPERATIVE VIDEONASOPHARYNGOSCOPY

SUBMUCOUS CLEFT PALATE – REPAIRED W FURLOW "Z" PALATOPLASTY. RESIDUAL BORDERLINE V P I. SECONDARY F. T.

International Journal of Pediatric Otorhinolaryngology

October 2016Volume 89, Pages 127–132

Velopharyngeal videofluoroscopy: Providing useful clinical information in the era of reduced dose radiation and safety

Pablo Antonio Ysunza; David Bloom; Kongkrit Chaiyasate; Matthew Rontal; Rachel VanHulle; Kenneth Shaheen; Donald Gibson

Affiliations
Speech Pathology Services, Ian Jackson Craniofacial and Cleft Palate Clinic, Neuroscience Program, Beaumont Health, Royal Oak, MI, USA

Publication History Published Online:August 11, 2016Accepted:August 9, 2016Received in revised form:August 8, 2016Received:July 5, 2016

Abstract
Full Text
Images
References

SURGICAL TREATMENT OF V P I

- **OPEN YOUR OPTIONS**
- **SECONDARY INTRAVELAR VELOPLASTY OR FURLOW**
- **FAT INJECTION**
- **SYNTHETIC INJECTION**
- **PHARYNGEAL FLAP**
- **SPHINCTER PHARYNGOPLASTY**
- **PLAN AND CUSTOMIZE !!**
- **INDIVIDUALIZE !!**
- **REMEMBER: SURGERY IS SCIENCE AND ART**


PROPERTY OF
WISCONSIN
ATHLETIC DEPT.

Beaumont Health
Beaumont + Botsford + Oakwood
More Beaumont. More Places.

GRACIAS POR SU ATENCION !!

BCBSMF

- antonio.ysunza@beaumont.edu
- ADDITIONAL INFORMATION
- REFERENCES
- COMMENTS
- DONATIONS
- GIFTS

OU WB